

Narrow band (light) imaging of oral mucosa in routine dental patients.

Part I: Assessment of value in detection of mucosal changes

Edmond L. Truelove, DDS, MSD ▪ David Dean, DDS ▪ Samuel Maltby ▪ Matthew Griffith
Kimberly Huggins, RDH ▪ Mickealla Griffith, DDS ▪ Stuart Taylor, DDS, MSD

The purpose of this investigation was to determine the value of adding narrow band (light) imaging (NBI) to the standard oral soft tissue examination process used to detect mucosal change. A total of 620 dental patients who came to the clinic for regular dental evaluation or for treatment of acute dental problems were given a standard oral soft tissue examination by dental students under faculty supervision. The results of the white light examination were recorded after the tissues were examined with NBI, at which point areas with a loss of fluorescence (LOF) were recorded. The nature of the tissue change was classified clinically as normal variation, inflammatory, traumatic, dysplastic, or other, and patients were categorized depending on their clinical findings: normal, need follow-up visit, or immediate biopsy. Risk factors related to oral dysplasia also were recorded. The addition of NBI added between one and two minutes to the examination process.

Of the 620 examinations, an area with an LOF suggestive of pathology was detected in 69 subjects (11.1%). After a second immediate evaluation, 28 of the 69 subjects were scheduled for follow-up or biopsy. None of the lesions discovered in these 28 subjects had been detected using standard (white light) examination.

Adding NBI to the routine clinical examination resulted in detection of changes not seen with white light examination in 11.1% of patients; of these, a small but important number were found to have otherwise undetected persistent changes representing inflammatory lesions or potentially dangerous oral dysplasia. Adding NBI as an adjunctive diagnostic procedure improved the quality and outcome of the examination process.

Received: August 31, 2010

Accepted: November 19, 2010

An important component of dental practice is the detection of changes to the oral mucosa and jaws that represent serious threats to health. Among these threats, the risk of oral cancer is a chief concern. Although the overall risk for cancer of the mouth and throat is relatively small, data from the American Cancer Society and National Cancer Institute predict that the lifetime risk of oral cancer is 1 in every 152 females and 1 in every 71 males.¹ The lifetime risk for developing oral cancer is greater than the lifetime risk for cancers of the brain, esophagus, and lymphomas, conditions that receive frequent public scrutiny as important risks for reduction in

life expectancy.¹ Oral cancer also is a significant problem because survival rates have improved only marginally during the past 50 years, with the five-year survival rate still only 53%.¹

Important risk factors for oral cancer include age, ethnic status, tobacco use, excess alcohol consumption, family history of cancer, and prior cancers.² The presence of some types of mucosal change, including leukoplakia, erythroplakia, proliferative verrucous leukoplakia, and lichen planus, also has been associated with an increased risk.³⁻⁶ Poor oral hygiene and lack of regular dental care are among suggestions as potential risk factors, either because of local inflammatory irritation or

because patients with poor access to care do not benefit from earlier detection of mucosal changes.⁷ Chronic mucosal infections, including candidiasis, herpes simplex, and human papilloma virus, also have been postulated as causing an increased risk for oral cancer.⁸⁻¹⁰

A factor that could be associated with poor prognosis is a delay in the detection and treatment of early oral cancers; however, data to support that hypothesis are not extensive.^{1,11-13} Still, if oral cancer behaves like most other cancers, it is logical to assume that very early detection and treatment is likely to result in better survival than delayed detection, which usually is associated with wider spread, metastatic nodes,

and regional spread to other organs. Some data exist that identify rates of progression from benign and premalignant to malignant for several types of oral lesions, but little actual data have been collected to demonstrate the value of routine oral examination of patients on reducing the risk of cancer and cancer morbidity.^{1,11,12} Some authors have suggested that there is little significant information to support the use of routine oral examination as a valuable tool to reduce morbidity or mortality.¹³

One of the difficulties associated with the clinical assessment of patients who could be at risk for oral cancer is that, until very recently, the only diagnostic method available has been visual and tactile examination of the oral mucosa. While that diagnostic process is reasonable, it cannot detect cellular changes that have not evolved enough to be visible to the unaided eye.

In the past, cancer detection and surveillance in other organ systems have suffered from the same limitations, with purely clinical observations proving to be inadequate in detecting premalignant or early malignant changes. Two excellent examples include the poor predictive value of visual inspection of the uterine cervix and breast self-examination. Until initiation of colposcopy and Pap smear evaluation of the cervix, cancer rates and deaths were significantly higher, while mammography has greatly improved detection and survival of patients with breast cancer.^{14,15} All three techniques are considered adjunctive diagnostic procedures designed to provide data to the clinician which, when included in a symptom report and risk factor assessment, can lead to more effective decision-making about the likelihood that a finding represents a potential neoplastic process that requires a

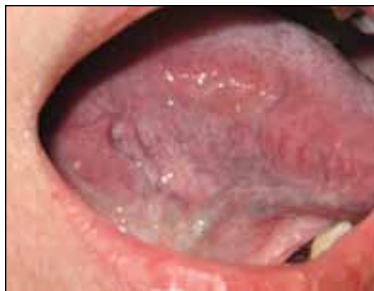

Fig. 1. Clinical photograph of the lateral tongue.

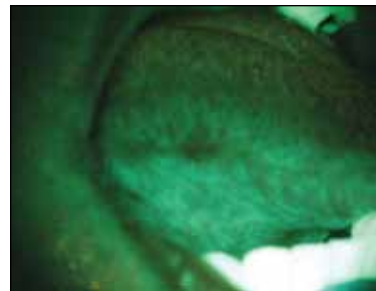


Fig. 2. Photograph of the same area as in Figure 1, demonstrating LOF that represents dysplasia.

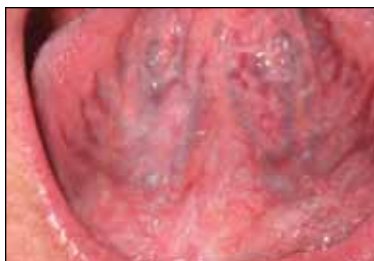

Fig. 3. Clinical photograph of the ventral tongue, showing normal to slightly atypical mucosa.

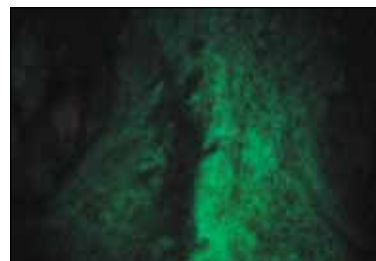


Fig. 4. Photograph of the same area as in Figure 3, demonstrating LOF that represents dysplasia.

biopsy or other more sophisticated diagnostic procedures.

The lack of effective adjunctive clinical diagnostic methods has clearly limited the ability of dental professionals to detect very early changes that could predict the presence of emerging inflammatory, premalignant, and dysplastic changes, leaving only visual inspection as the chief diagnostic tool. After visual detection of an observable change in the mucosa, clinicians have had access to two adjunctive diagnostic tools and one definitive tool to guide their decision-making: cytology, toluidine blue tissue staining, and biopsy.^{16,17} These methods have helped clinicians to decide whether a finding deserves more careful follow-up and management, and while all three methods remain important and valuable, they still

are limited due to their dependence on the presence of visible tissue changes to alert the clinician that further assessment is needed.

Methods to improve early detection of mucosal changes prior to their progression to a frank, clinical lesion state could improve prognosis and limit the morbidity associated with treatment. Narrow band (light) imaging (NBI) of tissues has been used extensively in other areas of the body as a means of identifying tissue changes that are either not visible to the unaided eye or uncharacteristic of a neoplastic process.¹⁸⁻²⁰ This method has been used to evaluate bronchial tissues and the mucosa of the intestinal tract, with findings that have demonstrated its potential utility.¹⁸⁻²⁰

Recently, studies funded by the NIH have investigated the use of NBI for the detection of changes

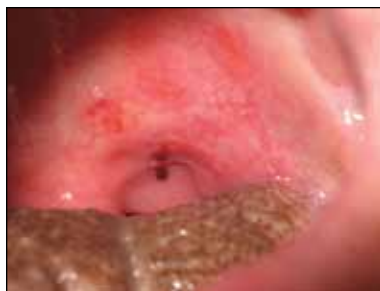

Fig. 5. Clinical photograph of herpes simplex of the palate.

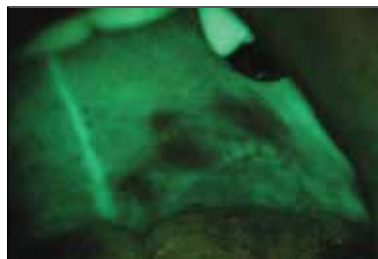


Fig. 6. Photograph of the same area as in Figure 5, demonstrating LOF that represents acute inflammation.

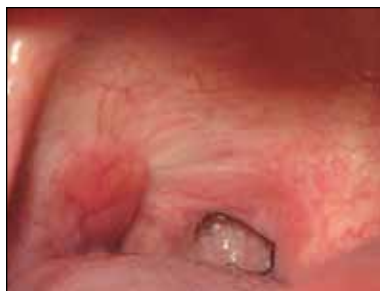

Fig. 7. Clinical photograph of the anterior tonsil pillar, illustrating the lymphoid tissues.

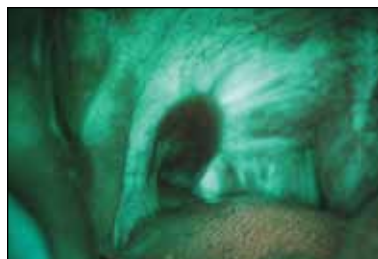

Fig. 8. Photograph of the same area as in Figure 7, demonstrating LOF that represents chronic inflammatory change.

in the oral mucosa associated with neoplasia or premalignant cellular change.^{21,22} These studies have shown that NBI has value in the detection of malignant disease and in the determination of surgical margins.²³ One result of these studies has been the development, FDA approval, and marketing of a NBI instrument, VELscope (LED Dental Inc.), that is designed for use in general practice settings.²⁴ Similar instruments are currently under development.

NBI uses a blue light directed at the oral mucosa and observed through an eyepiece that filters the light. Tissues with different physical, vascular, and cellular characteristics reflect or absorb the blue light, resulting in an image as viewed through the scope with different visual characteristics. The blue light augments the fluorescence

properties of some tissue components, generating a green-white appearance. On the other hand, the optical characteristics of some tissues result in a loss of fluorescence (LOF), causing a dark pattern when the tissues are observed through the scope. Inflamed and highly vascularized tissues absorb the light and appear dark compared to the same tissue without inflammation. Oral dysplasia and oral cancer also absorb the light and appear darker than the corresponding tissue without cancer or dysplasia. Dysplastic tissues with significant keratinization (leukoplakia) can exhibit increased fluorescence (whiteness) with LOF (darkness) around the periphery of the lesion. Obviously, because inflammatory lesions absorb the light and appear dark, traumatic, viral, and aphthous

lesions demonstrate an LOF, as do migratory glossitis and lymphoid tissue (Fig. 1–8).

Critics of the use of NBI have argued that the results are not sensitive or specific enough and can result in “false positive” findings that cause patients to be at risk for unnecessary invasive procedures.^{24,25} Others argue that the use of such adjunctive diagnostic devices is not necessary because risky mucosal changes are visible and can be detected with the unaided eye.²⁶

The difficulty with those opinions is that very early changes at the cellular level occur before the gross physical characteristics of the tissue have changed enough to create a clearly visible lesion that, when seen by the clinician, registers as a potentially important inflammatory or dysplastic lesion. Also, most adjunctive diagnostic methods are merely that—adjunctive—and are not intended to be definitive diagnostic tests. Application of strict standards of sensitivity and specificity in judging the relative value of these adjunctive methods could underestimate their potential for guiding the initial clinical decision-making as part of an overall assessment algorithm. Their chief use is to help clinicians discover changes that otherwise might not be observed or be of such a subtle nature that the clinician disregards the potential significance of the finding.

One study that assessed the value of NBI and toluidine blue in determining the nature of clinically detected lesions in a large group of adults who received oral examinations concluded that use did not improve the diagnosis of oral cancer; however, NBI was applied to only those patients who had clearly detectable oral lesions rather than being used as an adjunctive diagnostic process for all of



Fig. 9. VELscope with light shield.

the examinations.²⁴ Had this been done, it is likely that more cases of early dysplasia would have been detected. Application of the technology on all patients could have helped the examiners to identify changes that otherwise would have escaped recognition because of their nonspecific characteristics or lack of progression to a clearly visible state. Unfortunately, only a few studies have evaluated the application of NBI in routine dental practice, but one study has shown detection of premalignant changes that otherwise would have escaped detection.²⁷

Objectives

The purpose of this study was to evaluate the value of adding NBI of the oral mucosa for the detection of tissue changes to a standard oral examination in routine dental patients. The study also aimed to assess the relative value of NBI in the detection of inflammatory, dysplastic, and other tissue changes. The goal of the study was to assess the

value of adding NBI for the detection of oral changes not readily seen during normal, white-light examination of the oral mucosa. The purpose of the study was not to determine the absolute value of NBI in the detection of oral dysplasia or oral cancer, but to assess whether its use as an adjunctive diagnostic method adds value to standard examination processes. The study also was designed to test the value of this adjunctive method after only a brief examination to determine its value in normal general practice settings, rather than in settings where the modality would be employed by experts who regularly engage in diagnosis and management of mucosal lesions.

Materials and methods

Subjects

Patients seeking routine dental care or treatment for dental symptoms (pain, toothache, and so forth) were invited to participate in the study protocol. The study was approved as a quality improvement study by

the institutional review board of the University of Washington, and all patients entered into the study and signed consent after being informed of the study by one of the study investigators.

Study protocol

The study protocol included the following elements: Introduction of the patient to the study and obtaining consent to participate; routine social, medical, and dental histories; a head and neck physical examination, oral soft tissue assessment, and dental examination; recording of visual findings using a data collection form, scoring of tissue changes, and level of dysplasia suspicion (0–4); examination of mucosal tissues using a narrow band light source (VELscope), followed by recording the findings; scoring of type of tissue change and level of dysplasia suspicion (again, on a 0–4 scale); recording follow-up designations as None, Two-week, Four-week, Biopsy Next Visit, Biopsy This Visit, and Other; and recording of risk factors, including none, tobacco, alcohol, immunosuppressive disorder, immunosuppressive medication, cancer history, diabetes, and family history of cancer.

All patients were examined initially by third- and fourth-year dental students, then by the attending faculty of the clinic. Students were provided with a tutorial on conduct of the clinical and NBI methods with examples of normal findings, normal variation, changes caused by inflammatory disorders, and changes caused by dysplasia. The faculty of the clinic was provided with the same information as the students in a computer-based tutorial format. In addition, students and faculty were provided with an instruction packet for each patient enrolled in the study that

described the quality assurance study methodologies in addition to containing illustrated scoring sheets. Photographs of normal, variations of normal, and abnormal findings were provided digitally and in printed illustrations. The tutorial activity encompassed approximately one hour of information and instruction.

To facilitate efficiency, a total of five VELscopes were stationed in the clinic, which has a total of 12 operatories, and students accessed the VELscopes as they finished the clinical examination. Faculty supervised use of the VELscopes and interpretation of the clinical and NBI findings. The NBI was not carried out under the most ideal conditions because the clinic is a large, open facility and it was not possible to reduce the ambient room light. For this reason, each VELscope was fitted with a 12- or 14-inch black plastic disc with a hole in the center for the scope. This shield created a large shadow over the patient's mouth, greatly improving visualization for LOF; however, the viewing environment still was not as ideal as it would have been with the room light reduced. Nevertheless, this approach allowed for the detection of many areas of LOF. Figure 9 illustrates the VELscope equipped with the black shield for use in rooms that could not be completely dimmed.

Results

Five percent of subjects declined participation in the study after reading the consent form and discussing the study with an investigator. The most typical reason for a patient declining was concern that the light could cause harm or fear that an abnormality would be detected. Overall, patients were very accepting of the procedure and expressed great appreciation that an adjunctive

Table 1. Oral cancer risk factors for patients in this study (n = 620).

Risk factor	Percentage of all patients enrolled	Percentage of patients with significant LOF (n = 28)
Current tobacco use	21.5	32.1
Prior tobacco use	15.5	21.0
History of excess alcohol use	3.5	5.0
Poor oral hygiene	14.5	15.6
Diabetic in active treatment	9.5	11.5
History of any type of cancer	9.0	12.5
History of autoimmune disease or immunosuppressive medication	7.5	14.2

noninvasive diagnostic aid was available for their evaluation. The addition of the NBI protocol to the examination process added one to two minutes to the visit, not including the study consent process that is not part of a routine diagnostic procedure. Many patients reported personal experiences with friends or relatives who had developed oral cancer and other diseases of the mouth and commented positively about the thorough process being employed at the clinic.

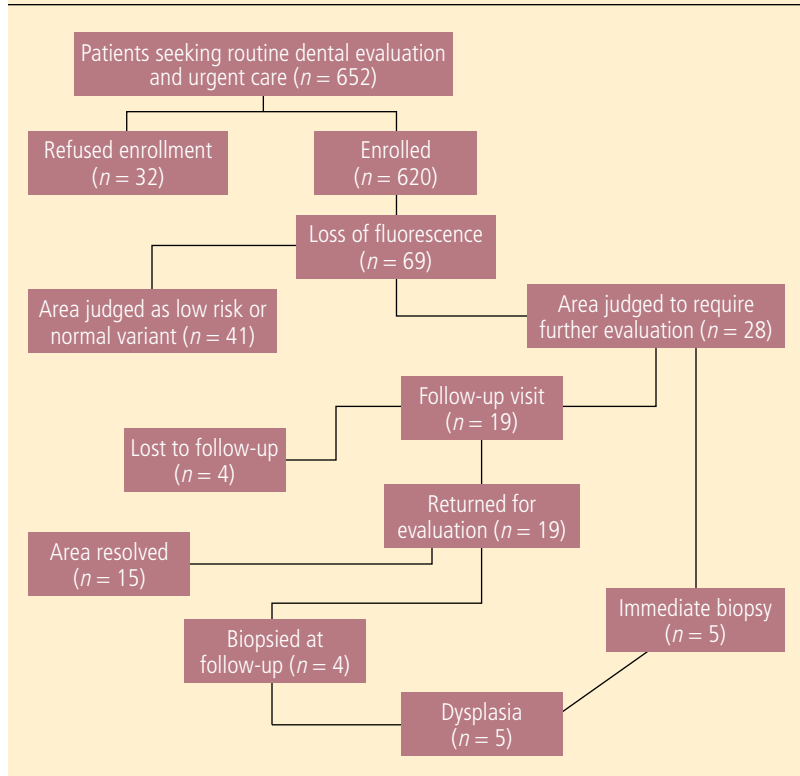
Patients ranged in age from 18–85, and 55% of the 620 patients were women. Of the patients who reported tobacco use, 21.5% reported active use and 15.5% reported prior tobacco use, with only a few patients reporting the use of smokeless tobacco. Nine percent of patients reported a prior history of some type of cancer, and 57% reported a family history of cancer. Nine percent of patients were diabetic and currently under treatment, while 7.5% identified themselves as having an immunological disorder or having used an immunosuppressive medication (Table 1).

LOF in areas that were reported as normal during the white light examination was detected in 69 patients. After immediate

re-evaluation, 41 patients were determined to have a region of subtle LOF that could be explained by normal variations in tissue characteristics, while 28 patients were scheduled for either immediate biopsy or a follow-up appointment. Five of those patients agreed to an immediate biopsy and four decided to follow up with their primary dental provider. The remaining 19 patients were scheduled for follow-up in two weeks. Of the 15 patients who returned for reassessment, the area of LOF had resolved and no clinical or NBI abnormality could be detected for 11 of them; this left four patients with persistent LOF compared to corresponding tissues. These LOF sites were biopsied in the same manner as the sites in the five patients who agreed to an immediate biopsy.

In all, nine patients (five during the initial assessment and four at the follow-up visit) were found to have tissue changes detected with NBI, but not white light, that were significant enough when considered in conjunction with the patient's history to require further diagnostic assessment. After the findings and risks were explained in addition to the alternatives to biopsy, all nine patients consented to biopsy,

Chart 1. Flow diagram of the study results.



although two of them received the biopsy at another facility due to insurance issues.

Of the nine patients who underwent biopsy, three were classified by histopathological assessment as having mild dysplasia and two were classified as having mild to moderate dysplasia (Chart 1). Two other patients were diagnosed as being histologically compatible with lichen planus, and the remaining two patients had inflammatory lesions (Table 2). Lesions detected during the white light examination are not included in this discussion and were handled in the routine manner used to manage visible oral lesions. The five dysplastic lesions that were detected with NBI were located in the buccal mucosa, the lateral border of the tongue, the lip, the palate, and the alveolar ridge.

The white light examination resulted in the detection of a variety of soft tissue lesions of the mucosa, but this study did not focus on those that were easily detected using standard visual inspection techniques. For the sake of completeness, a brief summary of the types of soft tissue lesions encountered using white light and NBI is listed in Table 3. These lesions included cheek bites, aphthous ulcers, herpetic lesions, migratory glossitis, fissured tongue, lichen planus, inflamed minor salivary duct openings, candidiasis, and cheilitis. Tonsillitis, pharyngitis, papillomas, scars, leukoplakia, and draining abscesses also were detected. Those lesions with inflammatory components demonstrated LOF, and in most cases the LOF provided a more dramatic presentation of the

extent and severity of the inflammatory change than the clinical examination did (Fig. 5–8).

The mucosal changes detected with white light, both white light and NBI, or NBI only were widely distributed throughout the mouth, with no distinct difference in pattern noted between the two different methods of assessment.

As previously described, a number of patients had mucosal changes detected with one or both types of visual assessments. Changes were noted in nearly half of all patients (305 of 620); however, the vast majority of them were found to be normal or minor variants and did not appear to represent significant pathology. The most common lesion was cheek bite, while the second most common was trauma to the tongue. Inflammatory changes to the oropharyngeal and tonsil areas also were common. Cheilitis and changes to the epithelium of the lips also were common and represented a range of etiologies that included habitual lip biting and actinic changes of the lower lip. A number of cases of lichen planus and generalized glossitis also were detected during the white light examination.

Although the study size was reasonably large, the diverse nature of lesions found and the wide range of risk factors associated with the development of oral lesions precluded development of specific associations between risk of mucosal change and a host of factors, including age, gender, tobacco use, diabetes, immunodeficiency, immunosuppressive medications, cancer history, family cancer history, and oral health status. Nevertheless, it is interesting to note that the patients with changes detected with white light, NBI, or both were more likely to carry one or more of the risk factors compared to those who had no areas of mucosal

Table 2. Biopsy results.

Lesion diagnosis	Number of patients
Lichen planus	2
Inflammation	2
Mild dysplasia	3
Mild to moderate dysplasia	2

change, with 54 of 69 patients (78%) who demonstrated LOF having either a history of tobacco use or current tobacco use. Those with mucosal lesions also were more likely to have poor oral hygiene.

Discussion

The purpose of this quality improvement study was to gain information about the clinical utility of one simple adjunctive diagnostic method (NBI) for the detection of mucosal changes. The rationale for the study assumed that such a diagnostic adjunctive method is not necessary to detect mucosal changes readily seen with normal white light examination methods. Existing data suggest that current examination methods are not sufficient for the earliest detection of mucosal changes that could represent inflammatory damage or the presence of very early dysplasia. This could partly account for the only modest reduction in oral cancer deaths since 1960.^{1,13}

There are several possible explanations for why oral cancer deaths and the stage of oral cancer at the time of diagnosis have not changed dramatically in the past 50 years.¹ The lack of improvement could relate to a number of factors, but when considering that the percentage of the population that receives regular dental care has increased in the past 50 years, it appears obvious that

Table 3. Types of lesions detected with combined clinical and NBI diagnosis methods.

Type of mucosal lesion detected	Relative frequency
Traumatic injury	Common
Lichen planus	Occasional
Dysplasia	Rare*
Cheilitis	Common
Migratory glossitis	Occasional
Fissured tongue	Occasional
Pharyngitis and tonsillitis	Common
Herpes simplex	Occasional
Recurrent aphthous	Occasional
Candidiasis	Occasional
Leukoplakia	Occasional
Mucosal bacterial infections	Rare
Inflamed minor salivary ducts	Occasional

Common = $\geq 10\%$ or greater; occasional = $< 10\%$; rare = $< 1\%$.
 *Near 1% prevalence in this study's population.

current diagnostic methods could benefit from one or more adjunctive approaches. Early detection of dysplasia in other organ systems has been acknowledged to be an important component in improving survival, so it is difficult to believe that early detection of potentially significant mucosal changes, whether they are inflammatory or dysplastic, would not lead to improvements in cancer-related outcomes.

Because oral cancer is a relatively uncommon condition, the authors did not expect to detect a large number of cases of dysplasia with either the white light examination or the use of NBI and were surprised that five cases of early dysplasia were identified. Of additional interest is the observation that NBI detected many areas of inflammation and vascular change not identified during the white light examination, suggesting that this methodology also could be useful in cataloguing instances of chronic

irritation and inflammatory change that, over time, could lead to irreversible conditions such as fibrosis, scarring, and leukoplakia.

While some might be concerned that detection of five unobserved cases of dysplasia seems higher than would normally be expected, it is important to point out that most experts believe that cellular atypia and early stages of dysplasia might not uniformly progress to more severe stages of oral cancer and that several cases of dysplasia exist for each case of oral cancer.^{6,11} Therefore, it is not quite so surprising that the rate of dysplasia found in the current study was 0.8%. American Cancer Society statistics state that the lifetime risk for developing oral cancer is less than 1 in 90, or approximately 1%, a figure not far from the 0.8% found in the population in the current study.²⁷ On the other hand, the rate detected in the current study might have been higher than expected among

routine dental patients seen in private practice settings because more than 60% of the patients enrolled in the study were seeking urgent care and might have had more risk factors (tobacco, poor oral hygiene, systemic disease, and so forth) than normal dental populations.

The study methodology was limited because it was carried out in a clinical setting that did not allow for a reduced ambient light examination environment. Based on the authors' experience in the use of NBI in darker settings, it is likely that a number of lesions viewed at the clinic with LOF went undetected. It is possible that one or more of these lesions might even have been dysplastic or an inflammatory change that could have benefited from further follow-up.

The study also was limited because the authors deliberately decided to use relatively inexperienced examiners, which might have resulted in lower rates of detection of mucosal changes for either method. The authors wanted to test the use of NBI in an environment that resembled a general dental setting more than a specialty clinic that focuses on the detection of mucosal lesions and disease. To that end, the results demonstrate the value of NBI when added to routine examination methods.

The study also could have been limited because it occurred in a university setting, where students and attending faculty might be more focused on mucosal assessment processes. A larger, multiple private office study would be useful, with general dentists and dental hygienists providing the white light and NBI process during normal patient care for both new and recall patients. It is encouraging, however, that this adjunctive diagnostic aid appeared to improve the detection

of mucosal changes not easily visible with white light examination.

The authors were pleased that adding the NBI to the examination process did not significantly increase the time required to evaluate patients when the study consent process was excluded. The authors also were pleased that patient response was strongly positive and that the study appeared to raise awareness among patients that the dental examination process extends beyond purely odontogenic issues and can encompass the detection of disorders that could have more severe and wider implications on their health.

Conclusion

The findings of this study support the use of NBI as a simple adjunctive diagnostic device that, when used as one component of a standard diagnostic protocol, could help clinicians to detect inflammatory and dysplastic tissues. Use of this technology could improve clinicians' ability to monitor and follow initially detected changes, and to better judge progression versus resolution and response to nonsurgical treatments. These findings need to be further explored in other settings to determine overall utility in general practice, but based on these findings, NBI appears to have the potential to assist general practitioners in assessment and decision-making related to mucosal tissues and lesions.

Acknowledgements

This study was made possible with funding from NIH grant #T32 DE07132 and LED Dental Inc.

Author information

Dr. Truelove is a professor, Department of Oral Medicine, University of Washington, Seattle, where

Dr. Taylor is a part-time faculty member and director of the urgent care clinic, Dr. Griffith is a full-time faculty member and teaches in the Diagnosis and Urgent Care Clinic, Ms. Huggins is a full-time affiliate faculty member and a member of the professional staff in the departments of Oral Medicine and Dental Public Health, and Mr. Maltby and Mr. Griffith are senior dental students. Dr. Taylor also maintains a private practice of oral medicine in Federal Way, WA. Dr. Dean is in private practice in Bellevue, WA.

References

- Howlader N, Noone AM, Krapcho M, Neyman N, Aminou R, Waldron W, Altekruse SF, Kosary CL, Ruhl J, Tatalovich Z, Cho H, Mariotto A, Eisner MP, Lewis DR, Chen HS, Feuer EJ, Cronin KA, Edwards BK, eds. SEER cancer statistics review, 1975-2008. Bethesda, MD: National Cancer Institute;2010. Available online at: http://seer.cancer.gov/csr/1975_2008/, based on November 2010 SEER data submission, posted to the SEER website, 2011.
- Divaris K, Olshan AF, Smith J, Bell ME, Weissler MC, Funkhouser WK, Bradshaw PT. Oral health and risk for head and neck squamous cell carcinoma: The Carolina Head and Neck Cancer Study. *Cancer Causes Control* 2010;21(4):567-575.
- Jaber MA. Oral epithelial dysplasia in non-users of tobacco and alcohol: An analysis of clinicopathologic characteristics and treatment outcome. *J Oral Sci* 2010;52(1):13-21.
- Wang YP, Chen HM, Kuo RC, Yu CH, Sun A, Liu BY, Kuo YS, Chiang CP. Oral verrucous hyperplasia: Histologic classification, prognosis, and clinical implications. *J Oral Pathol Med* 2009;38(8):651-656.
- Szarka K, Tar I, Feher E, Gall T, Kis A, Toth ED, Boda R, Marton I, Gergely L. Progressive increase of human papillomavirus carriage rates in potentially malignant and malignant oral disorders with increasing malignant potential. *Oral Microbiol Immunol* 2009;24(4):314-318.
- van der Waal I. Potentially malignant disorders of the oral and oropharyngeal mucosa: Terminology, classification and present concepts of management. *Oral Oncol* 2009;45(4-5):317-323.
- Schildt EB, Eriksson M, Hardell L, Magnuson A. Oral infections and dental factors in relation to oral cancer: A Swedish case-control study. *Eur J Cancer Prev* 1998;7(3):201-206.
- Yang SW, Lee YS, Chen TA, Wu CJ, Tsai CN. Human papillomavirus in oral leukoplakia is no prognostic indicator of malignant transformation. *Cancer Epidemiol* 2009;33(2):118-122.

-
9. Gandolfo S, Castellani R, Pentenero M. Proliferative verrucous leukoplakia: A potentially malignant disorder involving periodontal sites. *J Periodontol* 2009;80(2):274-281.
 10. Skamagas M, Breen TL, LeRoith D. Update on diabetes mellitus: Prevention, treatment, and association with oral diseases. *Oral Dis* 2008;14(2):105-114.
 11. Napier SS, Speight PM. Natural history of potentially malignant oral lesions and conditions: An overview of the literature. *J Oral Pathol Med* 2008;37(1):1-10.
 12. Weijers M, Ten Hove I, Allard RH, Bezemer DP, van der Waal I. Patients with oral cancer developing from pre-existing oral leukoplakia: Do they do better than those with *de novo* oral cancer? *J Oral Pathol Med* 2008;37(3):134-136.
 13. Shuman AG, Entezami P, Chernin AS, Wallace NE, Taylor JM, Hogikyan ND. Demographics and efficacy of head and neck cancer screening. *Otolaryngol Head Neck Surg* 2010;143(3):353-360.
 14. Pimple SA, Amin G, Goswami S, Shastri SS. Evaluation of colposcopy vs. cytology as secondary test to triage women found positive on visual inspection test. *Indian J Cancer* 2010;47(3):308-313.
 15. Ahmed NU, Haber G, Semanya KA, Hargreaves MK. Randomized controlled trial of mammography intervention in insured very low-income women. *Cancer Epidemiol Biomarkers Prev* 2010;19(7):1789-1798.
 16. Gupta A, Singh M, Ibrahim R, Mehrotra R. Utility of toluidine blue staining and brush biopsy in precancerous and cancerous oral lesions. *Acta Cytol* 2007;51(5):788-794.
 17. Mehrotra R, Singh MK, Pandya S, Singh M. The use of an oral brush biopsy without computer-assisted analysis in the evaluation of oral lesions: A study of 94 patients. *Oral Surg Oral Med Oral Pathol Oral Radiol Endod* 2008;106(2):246-253.
 18. Lee CT, Chang CY, Lee YC, Tai CM, Wang WL, Tseng PH, Hwang JC, Hwang TZ, Wang CC, Lin JT. Narrow-band imaging with magnifying endoscopy for the screening of esophageal cancer in patients with primary head and neck cancers. *Endoscopy* 2010;42(8):613-619.
 19. Mannath J, Subramanian V, Hawkey CJ, Ragu-nath K. Narrow band imaging for characterization of high grade dysplasia and specialized intestinal metaplasia in Barrett's esophagus: A meta-analysis. *Endoscopy* 2010;42(5):351-359.
 20. Katada C, Tanabe S, Koizumi W, Higuchi K, Sasaki T, Azuma M, Katada N, Masaki T, Nakayama M, Okamoto M, Muto M. Narrow band imaging for detecting superficial squamous cell carcinoma of the head and neck in patients with esophageal squamous cell carcinoma. *Endoscopy* 2010;42(3):185-190.
 21. Poh CF, Zhang L, Anderson DW, Durham JS, Williams PM, Priddy RW, Berean KW, Ng S, Tseng OL, MacAulay C, Rosin MP. Fluorescence visualization detection of field alterations in tumor margins of oral cancer patients. *Clin Cancer Res* 2006;12(22):6716-6722.
 22. Poh CF, Ng SP, Williams PM, Zhang L, Laronde DM, Lane P, Macaulay C, Rosin MP. Direct fluorescence visualization of clinically occult high-risk oral premalignant disease using a simple hand-held device. *Head Neck* 2007;29(1):71-76.
 23. Poh CF, Zhang L, Anderson DW, Durham JS, Williams PM, Priddy RW, Berean KW, Ng S, Tseng OL, MacAulay C, Rosin MP. Fluorescence visualization detection of field alterations in tumor margins of oral cancer patients. *Clin Cancer Res* 2006;12(22):6716-6722.
 24. Mehrotra R, Singh M, Thomas S, Nair P, Pandya S, Nigam NS, Shukla P. A cross-sectional study evaluating chemiluminescence and autofluorescence in the detection of clinically innocuous precancerous and cancerous oral lesions. *J Am Dent Assoc* 2010;141(2):151-156.
 25. Patton LL, Epstein JB, Kerr AR. Adjunctive techniques for oral cancer examination and lesion diagnosis: A systematic review of the literature. *J Am Dent Assoc* 2008;139(7):896-905.
 26. Jemal A, Siegel R, Xu J, Ward E. Cancer statistics, 2010. *CA Cancer J Clin* 2010;60(5):277-300.
 27. Huff K, Stark PC, Solomon LW. Sensitivity of direct tissue fluorescence visualization in screening for oral premalignant lesions in general practice. *Gen Dent* 2009;57(1):34-38.

Manufacturers

LED Dental Inc., Burnaby, British Columbia, Canada
888.541.4614, www.velscope.com

Exercise No. 287

Cancer Screening

Subject Code 736

The 15 questions for this exercise are based on the article "Narrow band (light) imaging of oral mucosa in routine dental patients. Part I: Assessment of value in detection of mucosal changes" on pages 281-289. This exercise was developed by Daniel S. Geare, DMD, in association with the *General Dentistry Self-Instruction* committee.

Reading the article and successfully completing the exercise will enable you to:

- understand the types of mucosal abnormalities;
- understand clinical methods of diagnosing mucosal abnormalities; and
- understand the value of narrow band (light) imaging in identifying mucosal changes.

1. Narrow band (light) imaging (NBI) is effective in detecting
 - A. dysplastic tissue changes.
 - B. changes in tissue color.
 - C. tissue thickness.
 - D. discrepancies between the tooth and the periodontium.
2. The purpose of NBI includes all of the following except:
 - A. Establishing the value of NBI in older, at-risk patients
 - B. Studying the value of adding NBI to a standard oral examination
 - C. To establish whether NBI can detect oral cancer
 - D. To determine whether oral examinations can be improved using NBI
3. The lifetime risk for developing oral cancer is greater than the risk of developing all of the following cancers except:
 - A. Brain
 - B. Esophageal
 - C. Lymphatic
 - D. Pancreatic

4. What is the five-year survival rate for oral cancer?
 - A. 25%
 - B. 46%
 - C. 53%
 - D. 69%
5. Which of the following has been associated with an increased risk of oral cancer?
 - A. Erythroplakia
 - B. Chronic bacterial infection
 - C. Chronic periodontitis
 - D. Acute traumatic injuries
6. Why is a visual and tactile examination limited in detecting oral cancer?
 - A. It cannot detect cellular changes
 - B. It is limited by the texture of the lesion
 - C. There are too many false positives
 - D. Oral lesions are too variable in color
7. Which of the following is not a risk factor for oral cancer?
 - A. Ethnic status
 - B. Excess alcohol consumption
 - C. Prior cancers
 - D. Chronic periodontal disease
8. NBI has been shown to have value in detecting
 - A. the extent of decay.
 - B. malignant disease.
 - C. blood flow in inflamed tissues.
 - D. the quality of the attached gingiva.
9. Diagnostic tools currently available to clinicians to measure mucosal changes include all of the following except:
 - A. Staining
 - B. Cytology
 - C. Biopsy
 - D. Computer imaging
10. Methods used to improve early detection of mucosal changes can
 - A. improve prognosis.
 - B. extend morbidity.
 - C. control mortality.
 - D. lower incidence.

-
11. NBI uses a blue light that detects all of the following tissue changes except:
- A. Physical
 - B. Vascular
 - C. Cellular
 - D. Texture
12. Inflamed and highly vascularized tissues absorb the light and appear dark. Oral cancer, by contrast, also absorbs light but appears lighter due to the cellular changes of the cancer cells.
- A. Both statements are true.
 - B. The first statement is true; the second is false.
 - C. The first statement is false; the second is true.
 - D. Both statements are false.
13. During this study, dysplastic lesions were detected in all of the following sites except:
- A. The lateral border of the tongue
 - B. The lip
 - C. The cheek
 - D. The alveolar ridge
14. Which of the following was among the most common mucosal changes detected by the white light examination?
- A. Cheek biting
 - B. Tongue bites
 - C. Candidiasis
 - D. Bacterial infection
15. There has been only a modest reduction in oral cancer deaths in the past 40 years. The existing data indicate that the examination methods have been insufficient for the early detection of mucosal changes.
- A. Both statements are true.
 - B. The first statement is true; the second is false.
 - C. The first statement is false; the second is true.
 - D. Both statements are false.
-



PACE
Program Approval for
Continuing Education

Approved PACE Program Provider
FAGD/MAGD Credit
Approval does not imply acceptance by a state or
provincial board of dentistry or AGD endorsement
06/01/2010 to 05/31/2014

*Answer form and Instructions are on pages 319-320.
Answers for this exercise must be received by June 30, 2012.*